

# Twin Forks Veterinary Clinic

## Equine Dental Care

### The Importance of Maintaining the Health of Your Horse's Mouth

Routine dental care is essential to your horse's in health. Periodic examinations and regular maintenance, such as floating, are especially necessary today for a number of reasons:

- We have modified the horse's diet and eating patterns through domestication and confinement.
- We demand more from our performance horses, beginning at a younger age, than ever before.
- We often select breeding animals without regard to dental considerations.

Proper dental care has its rewards. Your horse will be more comfortable, will utilize feed more efficiently, may perform better, and may even live longer.

### THE HORSE'S MOUTH

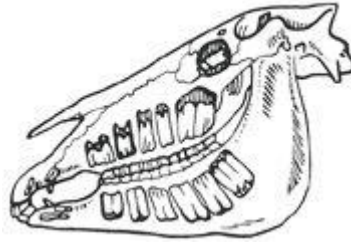
Horses evolved as grazing animals, and their teeth are perfectly adapted for that purpose. The forward teeth, known as incisors, function to shear off forage. The cheek teeth, including the molars and premolars with their wide, flat, grveled surfaces, easily grind the feed to a mash before it is swallowed.

Like humans, horses get two sets of teeth in their lifetime. The baby teeth, also called deciduous teeth, are temporary. The first deciduous incisors may erupt before the foal is born. The last baby teeth come in when the horse is about 8 months of age. These teeth begin to be replaced by adult teeth around age 2 1/2. By age 5, most horses have their full complement of permanent teeth. An adult male horse has 40 permanent teeth. A mare may have between 36-40, because mares are less likely to have canine (bridle) teeth.

The following chart shows the approximate ages at which different teeth erupt. By referring to it, you may detect potential abnormalities of your own horse associated with teething. For more information, refer to the Official Guide for Determining the Age of the Horse, published by the American Association of Equine Practitioners.

#### **Deciduous (Baby Teeth)**

1st incisors (centrals)	Birth or 1st week
2nd incisors (intermediates)	4-6 weeks
3rd incisors (corners)	6-9 months
1st, 2nd, & 3rd premolars (cheek teeth)	Birth or first 2 weeks for all premolars



### **Permanent (Adult Teeth)**

1st incisors (centrals)	2 1/2 years
2nd incisors (intermediates)	3 1/2 years
3rd incisors (corners)	4 1/2 years
Canines (bridle)	4-5 years
Wolf teeth (1st premolars)	5-6 months
2nd premolars (1st cheek teeth)	2 1/2 years
3rd premolars (2nd cheek teeth)	3 years
4th premolars (3rd cheek teeth)	4 years
1st molars (4th cheek teeth)	9-12 months
2nd molars (5th cheek teeth)	2 years
3rd molars (6th cheek teeth)	3 1/2 - 4 years

### **COMMON DENTAL PROBLEMS**

Horses may suffer from many dental problems. The most common include:

- Sharp enamel points forming on cheek teeth, causing lacerations of cheeks and tongue
- Retained caps (deciduous teeth that are not shed)
- Discomfort caused by bit contact with the wolf teeth
- Hooks forming on the upper and lower cheek teeth
- Long and/or sharp canine (bridle) teeth interfering with the insertion or removal of the bit
- Lost and/or broken teeth
- Abnormal or uneven bite planes
- Excessively worn teeth
- Abnormally long teeth
- Infected teeth and/or gums
- Misalignment/poor apposition (can be due to congenital defects or injury)
- Periodontal (gum) disease

### **RECOGNIZING DENTAL PROBLEMS**

Horses with dental problems may show obvious signs, such as pain or irritation, or they may show no noticeable signs at all. That is due to the fact that some horses simply adapt to their discomfort. For this reason, periodic dental examinations are essential. Indicators of dental problems include:

- Loss of feed from mouth while eating, difficulty with chewing, or excessive salivation
- Loss of body condition
- Large or undigested feed particles (long stems or whole grain) in manure
- Head tilting or tossing, bit chewing, tongue lolling, fighting the bit, or resisting bridling
- Poor performance, such as lugging on the bridle, failing to turn or stop, even bucking
- Foul odor from mouth or nostrils, or traces of blood from the mouth
- Nasal discharge or swelling of the face, jaw, or mouth tissues
- Oral exams should be an essential part of an annual physical examination by a veterinarian. Every dental exam provides the opportunity to perform routine preventative dental maintenance. The end result is a healthier, more comfortable horse.

## **FLOATING & PREVENTATIVE MAINTENANCE**

The process of rasping or filing a horse's teeth is known as floating. This is the most common dental procedure veterinarians perform on horses. Floating removes sharp enamel points and can create a more even bite plane. It also helps keep incisors and cheek teeth at a desirable length.



When turned out on pasture, horses browse almost continuously, picking up dirt and grit in the process. This, plus the silicate in grass, wears down the teeth. Stabled horses, however, may not give their teeth the same workout. Feedings are more apt to be scheduled, not continuous, and to include processed grains and hays. Softer feeds require less chewing. This may allow the horse's teeth to become excessively long or to wear unevenly. Adult horse's teeth erupt throughout their life and are worn off by chewing.

Unfortunately, cheek teeth tend to develop sharp enamel points even under normal grazing conditions. Because the horse's lower jaw is narrower than its upper jaw and the horse grinds its feed with a sideways motion, sharp points tend to form along the edges. Points form on the cheek side of the upper teeth and the tongue side of the lower teeth. These points should be rasped to prevent them from cutting the cheeks and tongue.

Floating is especially important in horses who have lost a tooth, or whose teeth are in poor apposition and do not fit together well. Normally, contact with the apposing tooth keeps biting surfaces equal. When cheek teeth are out of alignment, hooks can form.

If left unchecked, these hooks can become long enough to penetrate the hard or soft palate. Small hooks can be removed by floating. Longer hooks are usually removed with molar cutters or a dental chisel.

## **WOLF TEETH**

Wolf teeth are very small teeth located in front of the second premolar and do not have long roots that set them firmly in the jaw bone. They rarely appear in the lower jaw. A horse may have one, two, or no wolf teeth. While not all wolf teeth are troublesome, veterinarians routinely remove them to prevent pain or interference from a bit.

## **THE AGE FACTOR**

- The age of a horse affects the degree of attention and frequency of dental care required. Consider these points:
- Horses going into training for the first time, especially 2- and 3-year-olds, need a comprehensive dental check-up. Teeth should be floated to remove any sharp points and checked for retained caps. Caps should be removed if they have not been shed. This should be done before training begins to prevent training problems related to sharp teeth.
- Even yearlings have been found to have enamel points sharp enough to damage cheek and tongue tissue. Floating may improve feed efficiency and make them more comfortable.
- Horses aged 2-5 may require more frequent dental exams than older horses. Deciduous teeth tend to be softer than permanent teeth and may develop sharp enamel points more quickly. Also, there is an extraordinary amount of dental maturation during this period. Twenty-four teeth will be shed and replaced during this time, with the potential for 12 to 16 teeth to be erupting simultaneously. Horses in this age group should be examined twice yearly, and any necessary procedures should be performed.
- Even the best dental program may not be able to solve or alleviate all of a young horse's teething discomfort.
- Mature horses should get a thorough dental examination at least once a year, whether or not there are signs of tooth problems.
- It is important to maintain an even bite plane during a horse's middle teens in order to ensure a level grinding surface into its 20s. If you wait until the horse is in its 20s, the surfaces may be worn excessively and/or unevenly, and since the teeth are no longer erupting at this age, alignment may be impossible.

#### **DEVELOPING GREATER AWARENESS**

- If a horse starts behaving abnormally, dental problems should be considered as a potential cause.
- Teeth should be floated and maintained as indicated by an annual examination performed by an equine practitioner.
- Wolf teeth are routinely extracted from performance horses to prevent interference with the bit and its associated pain.
- Sedatives, local anesthetics, and analgesics can relax the horse and keep it more comfortable during floating and other dental procedures. Such drugs should be administered only by a veterinarian.
- Loose teeth are generally unhealthy teeth. If your equine practitioner finds a loose tooth, he or she will likely extract it. This reduces the chance of infection or other problems.
- Canine teeth, generally present in mature geldings and stallions and sometimes mares, are usually clipped and filed smooth to prevent interference with the bit. This also reduces the possibility of injury to both horse and human.
- Depending on the condition of your horse's teeth, more than one visit from your equine practitioner may be required to get the mouth in prime working order.
- It is important to catch dental problems early. Waiting too long may increase the difficulty of remedying certain conditions or may even make remedy impossible.
- Older horses should have their teeth checked at least twice yearly.

#### **MORE SERIOUS DENTAL AILMENTS**

Serious dental conditions can develop, such as infections of the teeth and gums, extremely long hooks on the molars, lost or fractured teeth, and others. These conditions may require surgical treatment and/or extraction by a veterinarian. Your equine practitioner can recommend the best treatment.